

# Management of Foreign Bodies in the Emergency Department

*T. Nagendran, MD*

**M**anagement of foreign bodies in the emergency department (ED) is a challenging and time-consuming experience. Although data are generally unavailable regarding the annual number of cases of foreign bodies treated in EDs, approximately 3000 deaths secondary to aspiration of a foreign body occur in the United States annually.<sup>1</sup> More than 50% of these cases occur in children younger than age 4 years, and the most common age group is 1 to 4 years; however, foreign body aspiration can also occur in children as young as age 6 months.<sup>1</sup> Failure to properly and completely manage a foreign body can lead to significant complications and even to litigation. Failure to explore an open wound for the presence of foreign bodies and subsequent wound infection is one of the most common causes for litigation in foreign body cases.

This article reviews the general considerations of managing patients who present with foreign bodies and discusses management according to specific body location and type of foreign body. In addition, a discussion of the author's experience managing more than 100 cases of foreign bodies in the ED is presented.

## GENERAL CONSIDERATIONS

Generally, removal of a foreign body may require greater time and effort than the physician initially anticipates. Unless the foreign body is readily seen or felt, ED physicians tend to underestimate the time needed to remove a foreign body located in subcutaneous tissues such as the heel.<sup>2</sup> When removing a foreign body from a frightened, uncooperative child, the physician should consider administering a sedative such as ketamine. The use of a sedative is preferred over physical restraints.

## Suspicion and Diagnosis

The history of a foreign body may not always be available, especially because foreign bodies are so common in children and mentally ill patients. The presence of a foreign body should be suspected in patients who present with severe infection, draining wounds, infection of

a sutured wound, draining from the ear or the nose, recurring pneumonia in the same location, and unexplained urethral or vaginal discharge. The sensation of a foreign body in the extremities is extremely helpful in locating a foreign body; however, a foreign body sensation in other body parts, such as the cornea and pharynx, may often be misleading. Minor scratches and abrasions in the cornea and pharyngeal wall can continue to cause the symptoms of foreign body sensation, even if the foreign body is no longer present.<sup>3</sup>

If the physician cannot see or feel the foreign body, then anterior-posterior and lateral radiographs of the soft tissue suspected of containing a foreign body should be ordered. Glass foreign bodies larger than 2 mm and gravel larger than 1 mm are radiopaque.<sup>2</sup> Organic materials such as wood are best seen by computed tomography (CT) scan.

## Removal

Removal of foreign bodies of the soft tissues in the absence of infection is not urgent and can be delayed for 24 to 48 hours so that removal can occur in an operating room (ie, in the best possible light).<sup>3</sup> If the foreign body is not easily accessible, then the patient should be referred to a surgeon after tetanus prophylaxis and antibiotic therapy for elective removal. However, button batteries should be removed immediately because they leak alkaline electrolytes and cause chemical injury and liquefaction necrosis.

After successfully removing a foreign body, the physician should always look for additional foreign bodies. Likewise, all patients presenting with wounds and lacerations should be explored for the presence of foreign bodies, and the ED medical record should reflect that the exploration failed to reveal any foreign body. All impaled foreign bodies should be removed

---

*Dr. Nagendran is Medical Director, Lafayette Family Care, Lafayette, AL, and Medical Director, Emergency Department, Randolph County Hospital, Roanoke, AL.*

by a surgeon in the operating room because removal can potentially cause a tamponade effect and uncontrollable bleeding.

#### **FOREIGN BODIES OF THE NOSE**

Foreign bodies of the nose are common in children and patients with mental disabilities. Pebbles, beads, marbles, peas, beans, nuts, button batteries, and paper wads are the most frequently encountered foreign bodies of the nose (**Figure 1**).<sup>1</sup> Often, the patient's history is sufficient to diagnose the presence of a foreign body of the nose. For example, the patient may have been observed placing a foreign body in the nose, or the patient may present with a history of unilateral, malodorous, purulent discharge. Patients with undiagnosed nasal foreign bodies may also present with body odor.<sup>4</sup>

Once the diagnosis of a foreign body of the nose is made, removal is indicated. This author uses and recommends the *positive pressure technique*, as described by Backlin and Cohen.<sup>5,6</sup> The positive pressure technique is successful in removing a smooth foreign body from the nose in almost all cases. This technique involves occlusion of the uninvolved nostril and the patient forcibly exhaling through the involved nostril; either the physician or patient can occlude the uninvolved nostril. If the patient is a child, a parent or guardian is asked to occlude the uninvolved nostril and blow air through the child's mouth, which forces the foreign body out. In these cases, the parent usually needs to blow only once or twice to force the foreign body out. By having the parent or guardian perform the procedure instead of the physician, the child remains more relaxed and is less likely to require sedation. If blowing into the patient's mouth is unsuccessful or if the physician decides against the mouth-to-mouth technique, then a tight-fitting mask and a bag-valve device can be used to produce the positive pressure.

If the positive pressure technique fails to expel the foreign body, then a long clamp and suction may also be used to extract a foreign body of the nose. The physician should pay careful attention to avoid dislodging the foreign body posteriorly, where the object may be aspirated into the airway. The patient should be placed in the Trendelenburg position to help prevent aspiration.

#### **Author's Experience**

Throughout this author's experience in EDs, a total of six children with nasal foreign bodies were treated. Five of the patients had beads in their noses. The positive pressure technique was used on these children and the beads were successfully removed. The sixth child had toilet tissue in the nose, which was removed with a hemostat.

#### **FOREIGN BODIES OF THE EAR**

##### **General Considerations**

The external ear canal narrows in two areas: at the junction of the cartilaginous part with the bony part and then at the isthmus of the bony part. Most foreign bodies are usually found in either of these two areas. The cross-section of the ear canal is elliptical in shape—knowing this shape and the shape of the foreign body helps in negotiating the foreign body in the appropriate direction. Every attempt should be made not to push the foreign body into or beyond the isthmus because removal becomes exceedingly difficult beyond this point. Insects, cotton, paper, jewelry, and button batteries are commonly encountered foreign bodies in the ear canal.

When managing a patient who presents with a foreign body of the ear, the physician should always check the patient's hearing before and after removal of the foreign body and appropriately document the findings. Also, patients with a perforated eardrum, patients with middle ear infection, and uncooperative patients should be referred to an otolaryngologist.

##### **Removal**

Up to 80% of foreign bodies of the ear can be removed by an ED physician. Methods of removal include suction, a right-angle nerve hook, a small alligator clamp, or irrigation. The irrigant can be either water or saline at room temperature; isopropyl alcohol is used when removing organic matter or cotton, which may swell with water. The patient should be seated in a semi-upright position. If the patient is a child, the child should be seated comfortably on a parent's lap.

Insects are the most common foreign bodies encountered in the ear canal, accounting for up to 80% of cases.<sup>7</sup> Shining light into the ear canal does not entice the insect to crawl out. This author contends that irrigation is the safest technique for insect removal. Killing the insect with mineral oil or lidocaine before irrigation is not necessary. A 20-mL syringe and butterfly needle catheter (ie, the butterfly needle is cut off, leaving approximately 1 inch of the catheter and the hub) are used.

In the case of a button battery in the ear, the foreign body must be removed immediately because batteries leak electrolyte solution. Irrigation, however, is not recommended because this technique may spread the electrolyte solution further. A right-angle nerve hook is recommended to remove button batteries from the ear canal.

##### **Author's Experience**

Thirty-six patients were treated: 30 of these patients were adults and six were children. The majority of adult

patients presented with the chief complaint of a foreign body in the ear. Most of the adult patients had an insect in the ear. One patient presented with the complaint of dizziness, and a large cockroach was found in his right ear during physical examination. All insects were removed by irrigation. One adult patient presented with a broken cotton applicator in her ear. The cotton applicator was removed with a clamp.

Of the six children, five had household items in their ear (eg, paper, cotton, nuts). The foreign bodies were removed either by suction or with a clamp. One child had an earring stuck at the tympanic membrane beyond the isthmus and was referred to an otolaryngologist.

## FOREIGN BODIES OF THE EYE

### General Considerations

In patients presenting with a foreign body of the eye, the first step is to rule out perforation of the globe of the eye by a penetrating foreign body. The foreign body may still be present as an intraocular foreign body, and the orbital contents may have herniated through the perforation site. The physician must always check the patient's visual acuity before and after removal of foreign bodies and appropriately document the findings. A detailed patient history and performance of a thorough, methodical examination of the eye are necessary. The physician should not stop examining after the first foreign body is found; the examination should be continued until all foreign bodies have been located.

### Perforation of the Globe

A foreign body propelled into the eye (eg, a workplace injury) causes perforation of the eye versus the non-perforating type of injury typically caused by a foreign body that is blown into the eye by wind. Of all eye perforation injuries, 70% to 90% are caused by hammering or using a machine tool.<sup>1</sup> Metal foreign bodies, such as iron (siderosis) and copper (chalcosis), are very toxic to the eye. Organic foreign bodies are sources of infection.<sup>8</sup> Although glass and plastic cause less inflammation to the eye, these substances are more difficult to locate in the globe because they are transparent.

There are many signs of a perforated globe, including decreased visual acuity, prolapse of orbital contents, flattening of the anterior chamber, absence of an afferent papillary reflex (eg, direct light reflex absent and consensual papillary reflex present), a tear-drop iris, a second iris, or a hole in the iris. If perforation of the globe is diagnosed, the physician must immediately obtain an eye consultation with an ophthalmologist. If a diagnosis is not confirmed but the patient's history suggests a globe perforation, a CT scan should be performed immediately and

an eye consultation should be obtained with an ophthalmologist. While awaiting the consult, the physician should manage the patient as follows:

- Administer a tetanus prophylaxis
- Take a culture of the conjunctival sac
- Administer antibiotic eye drops—do not use an ointment, which may cause intraocular granuloma
- Administer systemic, parenteral, broad-spectrum antibiotics (eg, first-generation cephalosporin and gentamicin)
- Administer an analgesic
- Administer an antiemetic to prevent vomiting, which may worsen the prolapse of orbital contents
- Keep patient from eating or drinking, in case surgery is needed
- Avoid any undue pressure on the globe, which may cause the protrusion of the orbital contents

After ruling out perforation of the globe and measuring the patient's visual acuity, a careful search for foreign bodies should be made with an ophthalmoscope or a slit lamp. The upper lid should be everted, and the cornea and the anterior chamber should be examined. Fluorescein dye and ultraviolet light should be used to detect corneal abrasions.

### Foreign Bodies of the Conjunctival Sac

Foreign bodies of the conjunctival sac can be removed with eye irrigation or with a wet cotton-tipped applicator (**Figure 2**). If the patient is unable to tolerate the examination and removal of the foreign body, then a drop of tetracaine can be instilled in the eye. The affected eye must be protected with an antibiotic ointment and eye patch. Patients with secondarily infected conjunctival foreign bodies, as evidenced by purulent discharge, must be immediately referred to an ophthalmologist.

### Foreign Bodies of the Cornea

Patients with deeply embedded corneal foreign bodies, secondarily infected foreign bodies with purulent discharge, and hypopyon should be immediately referred to an ophthalmologist. Superficial corneal foreign bodies can be removed either by irrigation, with a wet cotton-tipped applicator moistened with topical anesthetic, or with an insulin syringe needle (ie, the beveled edge of the insulin syringe needle is used to tease the foreign body off of the cornea).



**Figure 1.** Photograph of types of beads commonly found as foreign bodies of the nose in children.

Removal of the corneal foreign body should be performed under suitable light and with a magnifying lens. If a rust ring is left by a ferrous corneal foreign body, the patient must be referred to an ophthalmologist. After removal of the foreign body, antibiotic ointment and an eye patch should be applied. If a cycloplegic agent is used, the physician must ensure that the iris is not stuck to the back surface of the cornea and acting as a plug to seal off a perforation. Finally, the patient must be advised of the possibility of scar formation and subsequent vision impairment.

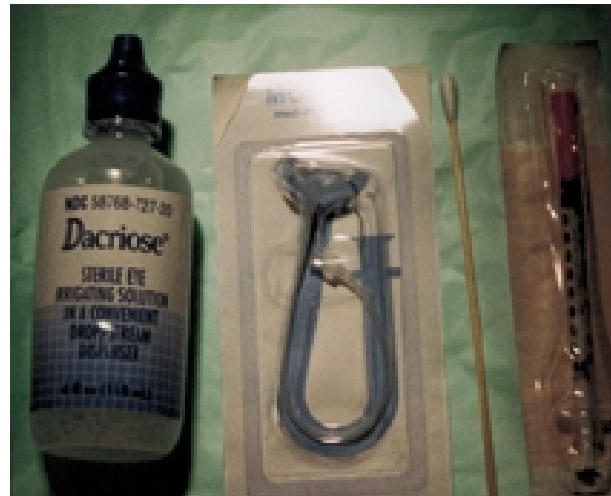#### **Conjunctival and Scleral Lacerations Made by a Foreign Body**

Superficial conjunctival lacerations need no repair and the treatment is essentially the same as conjunctival foreign bodies (ie, antibiotic ointment and an eye patch). In contrast, deep conjunctival laceration and scleral laceration require immediate ophthalmology referral.

#### **Author's Experience**

A total of 20 patients were treated for foreign bodies of the eye. Ten of these patients had foreign body sensation, but no foreign body was noted by the physician; all of these patients had traumatic conjunctivitis or corneal abrasions. Eight patients had foreign bodies in the cornea. For two of these patients, the foreign bodies were removed by the author with an insulin syringe needle; the other patients were referred to an ophthalmologist because the foreign bodies were deeply embedded. Two of these patients also had a rust ring.

One patient presented with pepper spray in both of his eyes. The eyes were irrigated with saline; an antibiotic ointment and eye patches were then applied. A follow-



**Figure 2.** Photograph of items used to remove ocular foreign bodies: irrigation solution, irrigation catheter, cotton applicator, and insulin syringe.

up appointment with an ophthalmologist was scheduled for the following day.

One patient presented with a penetrating injury to the right eye. While he was chasing a cow, a stick punctured his eye. The patient had only light perception in that eye. The treatment as outlined for perforation of the globe was administered and he was referred to an eye hospital.

### **FOREIGN BODIES OF THE AIRWAY**

#### **General Considerations**

The first and most important intervention for a patient who presents with a foreign body of the airway is to establish an effective airway and to provide adequate ventilation. Foreign bodies of the airway occur most commonly in children, individuals who wear dentures (because the palatal sensation is absent), and individuals with an impaired gag reflex (eg, alcoholic patients). Foreign bodies of the airway are also the most common cause of household accidental deaths in children younger than age 6 years.

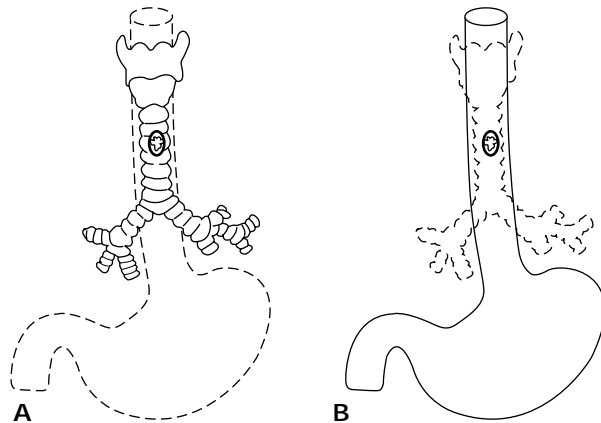
Aspiration of the foreign body is the most common cause of acute airway obstruction. Foreign body aspiration classically occurs in three stages: first, the patient is alert and trying to breathe but no air movement occurs; second, the patient becomes unconscious and pulses are still present; and third, the patient experiences cardiorespiratory arrest.

#### **Complete Airway Obstruction**

Fortunately, complete airway obstruction is less common today in the ED because well-trained paramedics

*(continued on page 32)*

(from page 30)



**Figure 3.** Illustration of A) a coin in the trachea that is oriented in the sagittal plane, in contrast to B) a coin in the esophagus in the coronal plane.

now effectively establish the airway at the scene. Alert patients should be encouraged by the paramedics to cough out the foreign body. If a patient loses consciousness, the Heimlich maneuver should be performed in older children and adults and back blows should be performed in choking infants. If the paramedics are unsuccessful in establishing an airway and the unconscious patient arrives in the ED with complete airway obstruction, then the physician should perform a jaw thrust maneuver to open the airway. The pharynx should then be carefully examined for the presence of the foreign body. If the foreign body is visualized, it should be removed with a finger sweep, suction, or with a long forceps (eg, Megill forceps). Direct laryngoscopy and an attempt to remove the foreign body may be tried before performing a cricothyrotomy. If the foreign body is subglottic in location, which is the case in 66% of fatal airway obstructions,<sup>9</sup> the physician must perform an immediate emergency cricothyrotomy in adults and in children older than age 12 years. For children younger than age 12 years, a needle cricothyrotomy using a 14-gauge intravenous cannula should be performed. After an effective airway is established, ventilation is accomplished with a bag-valve device.

#### Partial Airway Obstruction

Again, patients should be encouraged to cough out the foreign body. If the patient fails to cough out the foreign body and ventilation is adequate, radiographs of the neck and chest should be obtained. Once the diagnosis is confirmed, the patient should be immediately referred to an otolaryngologist or pulmonologist for the removal of the foreign body.

If a patient with partial airway obstruction also has dysphagia or odynophagia, then a foreign body of the esophagus should be suspected. Because the tracheal rings are incomplete posteriorly, any foreign body present in the esophagus can project into the tracheal lumen and compromise the airway.<sup>10</sup> **Figure 3** shows a coin in the trachea that is oriented in the sagittal plane in contrast to a coin in the esophagus in the coronal plane.

#### Café Coronary Syndrome

Café coronary syndrome is a type of upper airway obstruction caused by a food bolus at the level of the oropharynx or the hypopharynx. Café coronary syndrome is common in individuals who eat too fast, chew their food improperly (eg, swallowing a large meat bolus), are wearing dentures, are talking or laughing and eating simultaneously, or are drunk. The properly administered Heimlich maneuver promptly relieves the airway obstruction and forces the food bolus out. In some cases, 10 to 15 abdominal thrusts are necessary to dislodge the bolus.

#### Airway Obstruction in Specific Patient Populations

Patients who have had a cerebrovascular accident, have Parkinson's disease, or who are taking sedatives can choke on soft food (eg, cheese, peanut butter). In such cases, establishing the airway may be extremely difficult because the soft and thick consistency of such foods complicates digital or instrumental removal and makes suction impossible. An endotracheal tube should be placed to establish the airway, and then the obstructing food material can be removed from the oropharynx.

#### SWALLOWED FOREIGN BODIES

##### General Considerations

Generally, foreign bodies are swallowed by children, geriatric patients, and individuals who are cognitively or functionally impaired. Foreign bodies are swallowed either accidentally (eg, in children) or intentionally (eg, in prisoners). Of foreign bodies of the gastrointestinal tract, 80% to 90% pass through spontaneously without any complication, but 10% to 20% must be removed endoscopically and 1% require surgical removal. Complications of swallowed foreign bodies include perforation (eg, if the foreign body is a sharp object such as a fish or chicken bone), obstruction, and bleeding.

##### Foreign Bodies of the Esophagus

The esophagus is the least distensible part of the gastrointestinal tract, which contributes to the entrapment of foreign bodies. First, perforation of the esophagus should be ruled out. Perforation of the cervical

esophagus presents with subcutaneous emphysema of the neck, and the thoracic esophagus produces mediastinal emphysema and mediastinitis.

Of all cases of foreign bodies of the esophagus, 80% occur in children. Coins are the most frequently encountered foreign body in this patient population. In adults, chicken and fish bones are the most common type of foreign body of the esophagus and commonly cause perforation. Foreign bodies are commonly lodged at the level of the sixth cervical vertebra where the cricopharyngeus ends, at the level of the aortic arch, and at the gastroesophageal junction. In addition, obstruction may also occur at pathologically narrowed parts of the esophagus (eg, stricture, tumor). Similar to café coronary syndrome, patients who are drunk or patients who eat fast or swallow without chewing properly may experience an obstruction of the distal esophagus known as *steak house syndrome*. If patients with an esophageal foreign body complain of chest pain, an electrocardiogram should be ordered to rule out acute myocardial infarction. Obstruction of the esophagus causes localized discomfort, and obstruction at the level of gastroesophageal junction causes referred pain at the suprasternal notch.

The physician must establish, maintain, and protect an effective airway at all times. Diagnosis is usually suggested by the patient's history, and obstruction of the esophagus produces drooling and/or vomiting. A barium study confirms the diagnosis. If perforation is suspected and clinical findings are inconclusive, a lateral soft-tissue radiograph of the neck and posterior-anterior and lateral chest radiographs should be performed. In cases of cervical esophageal perforation, radiography reveals the foreign body and air in the soft tissues or in the retropharyngeal space; in cases of thoracic esophageal perforation, mediastinal emphysema is seen. A CT scan of the neck and a meglumine diatrizoate (not barium) swallow may further delineate the perforation site. Perforation of the esophagus is a surgical emergency and appropriate consultations must be obtained immediately.

**Swallowed coins and other blunt, smooth objects.** Most swallowed coins and other blunt, smooth objects pass into the stomach without medical intervention. However, these smooth foreign bodies may need to be removed endoscopically using an appropriate tool, such as a basket or loop, if the foreign body is stuck at the gastroesophageal junction. A coin at the gastroesophageal junction can be safely observed for 12 to 24 hours in an otherwise healthy patient. Foley catheter removal by the ED physician is no longer recommended because endoscopic removal by a gastroenterologist is much safer.

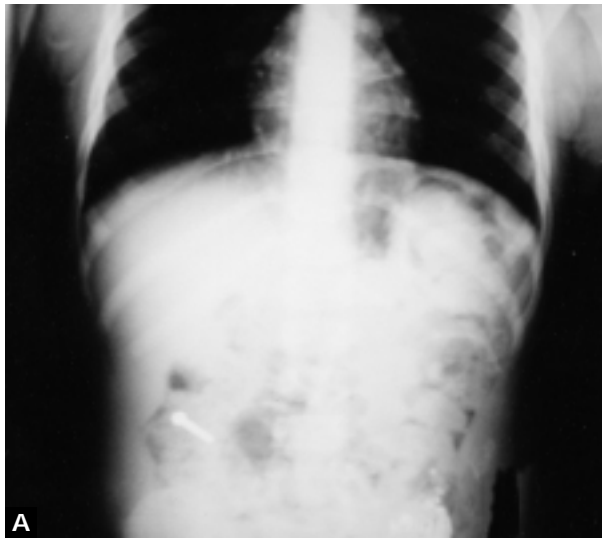
**Alkaline batteries.** Swallowed alkaline batteries leak

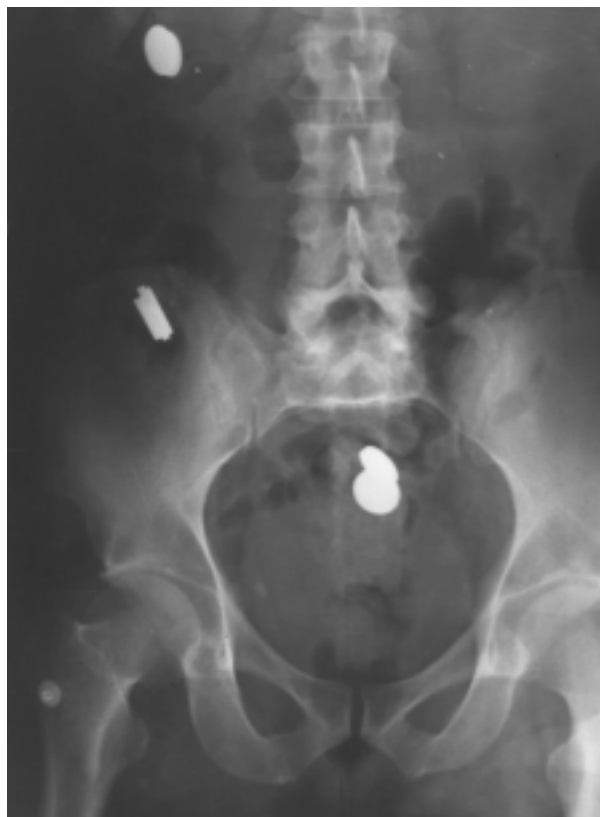
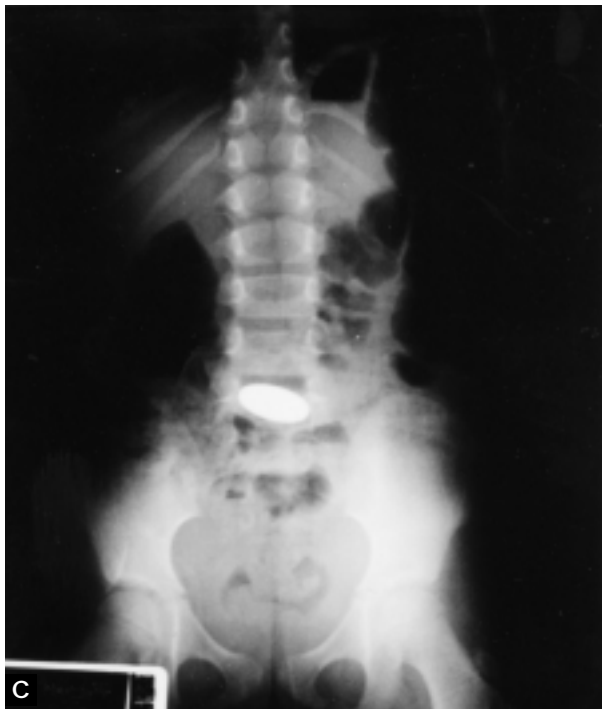
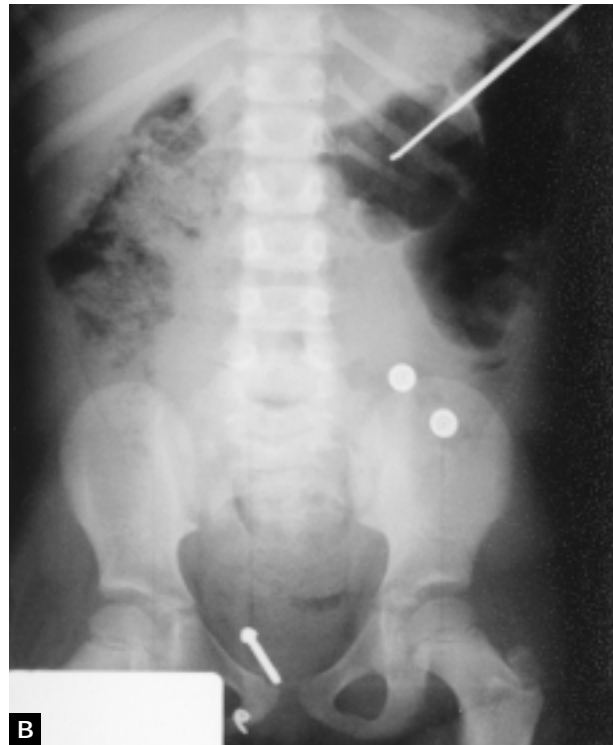Figure 4. Swallowed foreign bodies: radiograph showing coins ingested by a psychiatric patient.

electrolyte solution and concentrated potassium hydroxide, which causes liquefaction necrosis. Pressure necrosis and mercury toxicity may also occur, depending on the size and type of the battery. For specific information about the type of poisoning with each battery, the phone number for the National Battery Hot Line (Poison Control Center) is (202) 625-3333. The presence of button batteries in the esophagus is considered an emergency, and all batteries must be removed endoscopically as soon as possible after diagnosis.

**Food bolus at the gastroesophageal junction (steak house syndrome).** After confirming the diagnosis by barium swallow, intravenous glucagon (1 mg in adults; 0.2 to 0.4 mg in children) and/or gas-forming agents (eg, Z-gas or soft drinks) effectively relieve obstruction in most cases. Sublingual nifedipine and nitroglycerin have also successfully relieved this type of obstruction. Another technique to relieve the obstruction is to have the patient drink a large amount of water (ie, two to three glasses) and then perform the Valsalva maneuver. If all of these measures fail, endoscopic removal of the



**Figure 5.** Swallowed foreign bodies: A) and B) radiographs of a metal screw ingested by a 3-year-old girl. The child presented with vague abdominal pain, and a history of the foreign body was not available. When her condition did not improve, plain radiography of the stomach demonstrated a foreign body (a metal screw). The patient passed the screw through the digestive tract in 17 days with no complications. C) Radiograph of a quarter ingested by an 11-year old boy. The quarter passed safely through the digestive tract.

foreign body is performed. The foreign body can also be endoscopically pushed into the stomach. All adult patients with steak house syndrome should undergo further diagnostic workup to rule out the presence of an obstructing esophageal lesion (eg, cancer, stricture).

**Foreign bodies of the stomach and small intestine (Figures 4 and 5).** Observation is the treatment of choice for foreign bodies of the stomach and intestine because most of these objects, unless extremely large or sharp, pass through without any complication. Patients

should be followed by daily plain radiograph of the abdomen. Also stool guaiac testing should be performed to rule out bleeding. Foreign bodies of the stomach and small intestine may cause complications such as obstruction, perforation, and bleeding. Obstruction usually occurs at the ileocecal junction.

Although button batteries release toxic substances such as mercury into the stomach, batteries less than 23 mm have been observed to pass through the pylorus and gastrointestinal tract without difficulty.

*(continued on page 37)*

(from page 34)

Button batteries larger than 23 mm and any other batteries that fail to pass through the pylorus after 3 to 4 days of observation may have to be removed endoscopically.

**Body packer syndrome.** Cocaine smugglers may ingest cocaine-filled condoms or balloons to smuggle the drugs into the United States. If these packets rupture and are absorbed, as little as 1 g of cocaine can be fatal.<sup>11,12</sup> Immediate surgical removal of these packets is recommended.<sup>11,12</sup>

#### Author's Experience

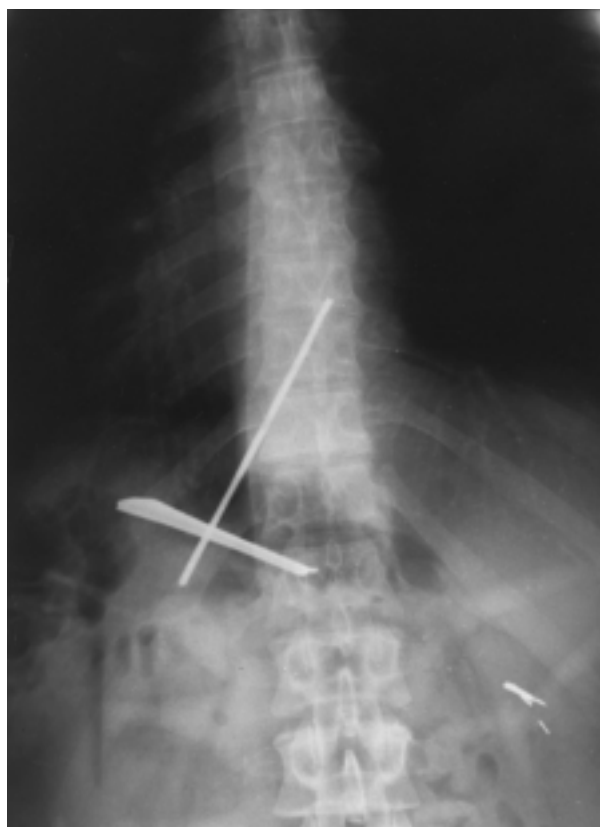The author has seen five cases of foreign bodies of the esophagus. Two of the cases involved children with coins in the esophagus. In both cases, the coins passed into the stomach while the child was in the ED. One adult patient presented with cervical esophageal perforation by a fish bone, which was confirmed by CT scan. One case of steak house syndrome was seen. In this case, the patient did not respond to intravenous glucagon or oral soft drinks. A meat bolus was endoscopically removed by a gastroenterologist, and a benign stricture was found at the gastroesophageal junction. One patient presented with a fish bone in the pharynx, which was removed by a Kelly clamp.

The author has seen six cases of foreign bodies of the stomach or small intestine. One patient, who was addicted to meperidine, swallowed various kinds of foreign bodies (**Figure 6**) so that he could receive intravenous meperidine during endoscopy. This patient underwent celiotomy for the removal of the foreign bodies. Four other patients presented with smooth foreign bodies, all of which passed through the gastrointestinal tract and were excreted. One child presented with a staple in the stomach. Although a staple is a sharp object, the gastroenterologist elected to observe the patient because the staple was small. The foreign body passed through without any complications.

#### FOREIGN BODIES OF THE RECTUM

Foreign bodies of the rectum usually occur in individuals who engage in various anal sexual practices. After rectal and abdominal examination, an erect abdominal radiograph should be performed to rule out free air under the diaphragm. Presence of free air and/or signs of peritonitis are an indication for celiotomy to remove the foreign body and for closure of the perforation. Perforation is common with foreign bodies that are located above the peritoneal reflection.

Before manipulation of the foreign body, rectal perforation and peritonitis must be ruled out. Although most rectal foreign bodies are readily palpable on



**Figure 6.** Swallowed sharp foreign bodies: radiograph showing a broken fork and a metal rod in a psychiatric patient. The foreign bodies were removed surgically.

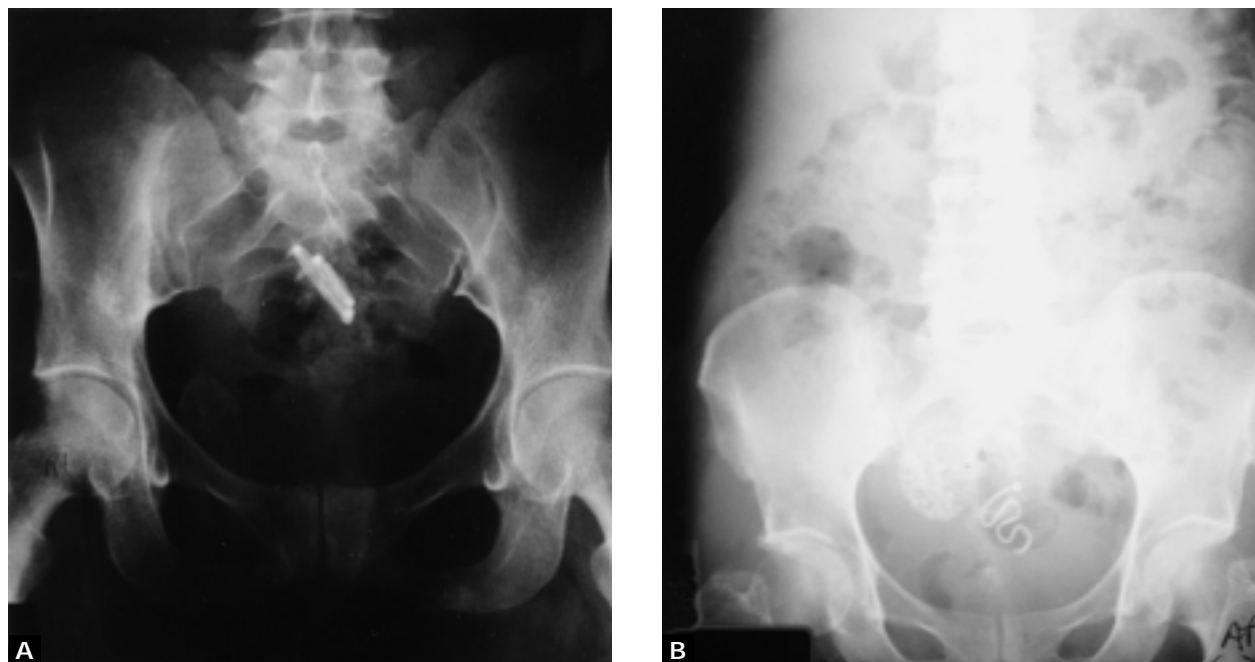
examination, removal is often difficult because of the spasm of the sphincter or the intraluminal suction proximal to the foreign body. Low-lying foreign bodies can be removed through an anoscope while the patient is under circumanal sphincter block. Intraluminal suction can be overcome by placement of a Foley catheter and inflating the balloon. After removal of all rectal foreign bodies, another erect abdominal radiograph should be performed to again rule out free air under the diaphragm.

#### FOREIGN BODIES OF THE VAGINA

Foul-smelling vaginal discharge in a patient of any age group should alert the clinician to the possibility of a foreign body. In children, toilet paper is the most commonly encountered foreign body of the vagina; in adults, the most common foreign body of the vagina is a retained tampon. **Figure 7** shows radiographs of foreign bodies of the vagina (retained intrauterine devices).

A detailed vaginal examination with a speculum in adults and with a vaginoscope in children should be





**Figure 7.** Radiographs of two patients who presented with vague pelvic pain and were found to have retained intrauterine devices.

performed. Some children may need conscious sedation. An otoscope can be used to examine the vagina in children. If the foreign body is toilet paper, a vaginal lavage is the best method for removal. A hard foreign body (eg, a crayon) can be felt by inserting a finger in the patient's rectum; a hard foreign body may also be removed by milking it out of the vagina with the finger in the rectum.

#### **Author's Experience**

The author has treated five adults with foreign bodies of the vagina. Two patients presented for a "missing" tampon, two patients presented with vague pelvic complaints, and the fifth patient presented with foul-smelling discharge. The patient with foul-smelling discharge had a retained tampon, which was removed under direct vision. The two patients with vague pelvic complaints were found to have retained intrauterine devices, and the other two patients failed to show any tampon either under speculum examination or in the radiograph of the abdomen and pelvis.

#### **FOREIGN BODIES OF A WOUND**

If a patient presents to the ED with either a laceration or a puncture wound, the wound should be explored for the presence of a foreign body and the exploration and findings should be documented in the

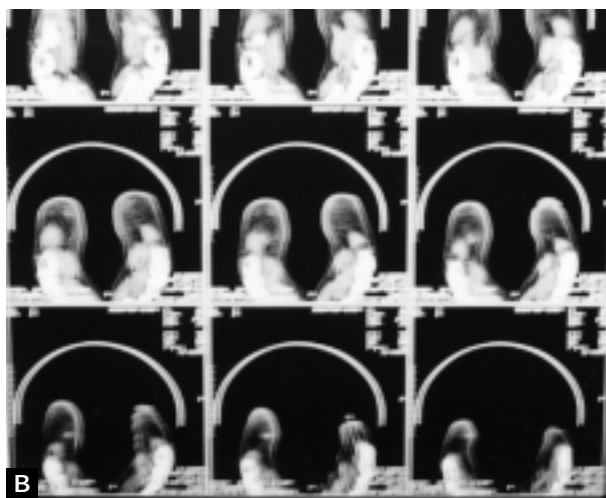
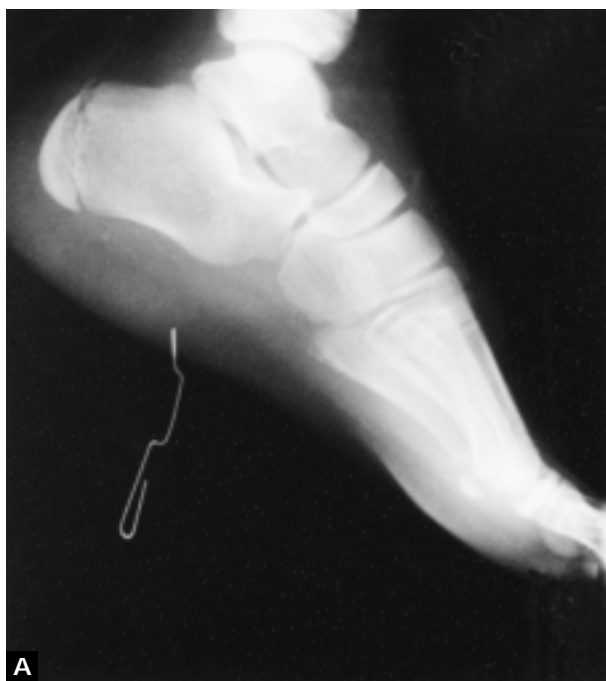medical record. Complete hemostasis, good lighting, and a magnifying lens are mandatory for the successful removal of foreign bodies in a wound.

All wounds, including puncture wounds, should be palpated for the foreign body sensation. Inordinate pain, increased pain with movement, and point tenderness to palpation should make the clinician suspicious of the presence of a foreign body in the wound. Also, a nonhealing wound or an infected wound should raise the possibility of a retained foreign body.

All metal and glass objects that are larger than 2 mm and gravel larger than 1 mm can be accurately seen on a plain radiograph.<sup>7</sup> Wooden and aluminum foreign bodies are radiolucent. Radiographs can confirm a foreign body; however, this technology should not be substituted for a detailed clinical examination. A CT scan should be ordered to visualize a wooden foreign body (**Figure 8**).

Removal of a foreign body in an uninfected wound is not urgent. Patients may be referred to a surgeon for elective removal of foreign body. Meanwhile, patients should receive tetanus prophylaxis and prophylactic antibiotics.

If the foreign body is removed in the ED, the patient should be advised that there is a possibility that all foreign bodies were not found and that the patient may have to be referred to a surgeon at a later point. All

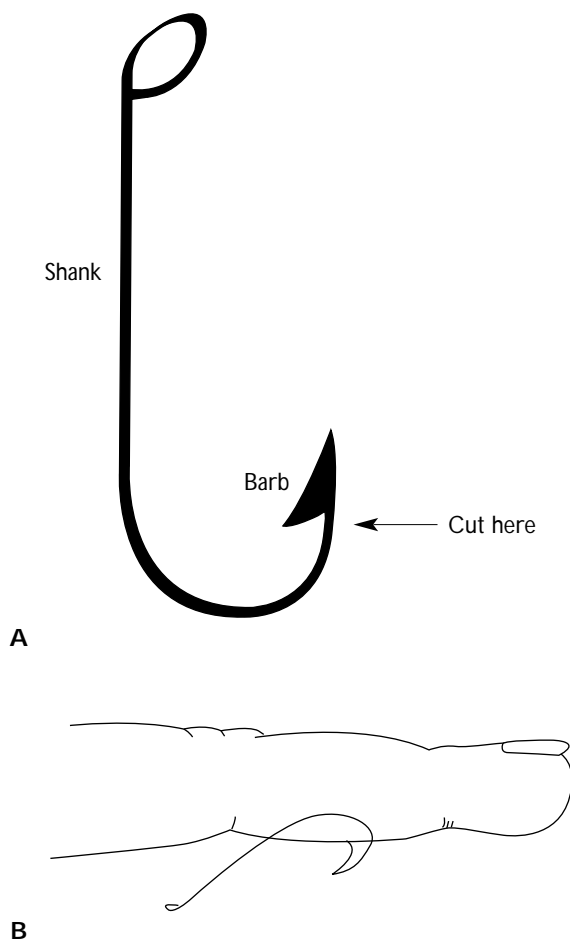


**Figure 8.** Wood splinter and an infected wound in the foot of a teenage patient. A) Conventional radiography does not show the wood splinter. A paper clip is used to show the puncture wound site. B) Computed tomography scans reveal the wooden splinter, which was removed in the operating room by a surgeon.

impaled foreign bodies of the neck, skull, eyes, and heart should be removed in an operating room where a surgeon can control the bleeding.

**Author's Experience**

Thirty-two cases of a foreign body in a wound were



**Figure 9.** Illustration of A) a standard fish hook and B) a fish hook as a foreign body of the finger. The physician should always cut the hook at the barb before attempting to remove the hook.

treated. Almost all of these foreign bodies were present in the patients' feet, secondary to walking barefoot. The two most commonly seen foreign bodies were nails and pieces of glass. The patient in Figure 8 had a wood splinter in his foot and was referred to a surgeon because he was frightened and needed general anesthesia for removal of the foreign body. Except for the patient in Figure 8, all other patients were treated in the ED because the foreign body was readily seen or felt. One patient who had been drinking alcohol presented with a laceration. Clinical evaluation failed to reveal any evidence of foreign body and the wound was closed. Subsequent radiography demonstrated a piece of glass embedded deep in the wound, but the patient would not permit the wound to be reopened. The patient was advised to see his private physician.

## MISCELLANEOUS FOREIGN BODIES

### Fish Hooks

Although there are many types of manufactured fish hooks, the barb in all fish hooks keeps the point of the hook embedded in tissue and resistant to removal (**Figure 9**). Fish hooks are safely removed by cutting the barb with a wire cutter and then removing the remainder of the hook retrospectively through the original entry site. If the barb is not accessible outside the skin, the physician should push it through sterilized and anesthetized skin and then cut the barb. The physician should take extreme caution to avoid vital structures (eg, blood vessels, nerves) before this procedure is performed. All patients should receive tetanus prophylaxis and oral antibiotics.

**Author's experience.** The author has treated ten male patients (ranging in age from 10 to 80 years) for fish hook injuries. Seven of these patients had a hook stuck in the hand or finger. Other areas involved were scalp, face, and buttocks.

### Subungual Foreign Body

Subungual foreign bodies are extremely painful and failure to remove them completely leads to osteomyelitis of the distal phalanx. Splinters are the most common subungual foreign body. If the splinter is visible, it is simply pulled out with a splinter forceps. If the splinter is completely buried under the nail plate, then a wedge of the nail is removed to expose the foreign body, allowing the physician to remove it. **HP**

## REFERENCES

1. Rosen P, Barkin RM, Braen CR, et al, eds: *Emergency Medicine: Concepts and Clinical Practice*, 3rd ed. St. Louis, MO: Mosby Year Book, 1992:319-337.
2. Howell JM, Chisholm CD: Wound care. *Emerg Med Clin North Am* 1997;15:417-425.
3. Jenkins JL, Loscalzo J, Braen GR: *Manual of Emergency Medicine*, 3rd ed. Boston: Little, Brown, 1995.
4. Moriarty RA: Nasal foreign body presenting as an unusual odor. *Am J Dis Child* 1978;132:97-98.
5. Backlin SA: Positive-pressure technique for nasal foreign body removal in children. *Ann Emerg Med* 1995;25:554-555.
6. Cohen HA, Goldberg E, Horev Z: Removal of nasal foreign bodies in children [letter]. *Clin Pediatr (Phila)* 1993;32:192.
7. Fritz S, Kelen GD, Sivertson KT: Foreign body of external auditory canal. *Emerg Med Clin North Am* 1987;5:183-192.
8. Strange GR, Ahrens W, Lelyveld S, Schafermeyer R: *Pediatric Emergency Medicine: A Comprehensive Study Guide*. New York: McGraw-Hill, Health Professions Division, 1999.
9. Craig RM: Esophageal disorders: inflammatory disease, foreign bodies and esophageal obstruction, and caustic injury. *Hospital Physician Gastroenterology Board Review Manual* 1998;4(2):1-14.
10. Beer S, Avidan G, Viure E, Starinsky R: A foreign body in the esophagus as a cause of respiratory distress. *Pediatr Radiol* 1982;12:41-42.
11. McCarron MM, Wood JD: The cocaine "body packer" syndrome. Diagnosis and treatment. *JAMA* 1983;250:1417-1420.
12. Caruana DS, Weinbach B, Goerg D, Gardner LB: Cocaine-packet ingestion: diagnosis, management, and natural history. *Ann Intern Med* 1984;100:73-74.

## SUGGESTED READING

- Coleman DJ, Lucas BC, Rondeau MJ, Chang S: Management of intraocular foreign bodies. *Ophthalmology* 1987;94:1647-1653.
- Dailey RH: Acute upper airway obstruction. *Emerg Med Clin North Am* 1983;1:261-277.
- De Juan E Jr, Sternberg P Jr, Michels RG: Penetrating ocular injuries: types of injuries and visual results. *Ophthalmology* 1983;90:1318-1322.
- Ferrucci JT Jr, Long JA Jr: Radiologic treatment of esophageal food impaction using intravenous glucagon. *Radiology* 1977;125:25-28.
- Friedman EM: Foreign bodies in the pediatric aerodigestive tract. *Pediatr Ann* 1988;17:640,642,644-647.
- Herbst AL: *Comprehensive Gynecology*, 2nd ed. St. Louis, MO: Mosby-Year Book, 1992.
- Jacobson S: Upper airway obstruction. *Emerg Med Clin North Am* 1989;7:205-217.
- Mittleman RE, Wetli CV: The fatal café coronary. Foreign-body airway obstruction. *JAMA* 1982;247:1285-1288.
- Nagendran T, Nagendran S: Foreign bodies of gastrointestinal tract. *J Med Assoc State Ala* 1981;51:31-35.
- Newell SW: Management of corneal foreign bodies. *Am Fam Physician* 1985;31:149-156.
- Rice BT, Spiegel PK, Dombrowski PJ: Acute esophageal food impaction treated by gas-forming agents. *Radiology* 1983;146:299-301.
- Schwartz GR, Cayten CG, et al, eds: *Principles and Practice of Emergency Medicine*, 3rd ed. Philadelphia: Lea & Febiger, 1992.
- Stenchever MA: *Office Gynecology*, 2nd ed. St. Louis, MO: Mosby, 1996.
- Webb WA: Management of foreign bodies of the upper gastrointestinal tract. *Gastroenterology* 1988;94:204-216.

Test your knowledge and comprehension of this article with Review Questions on page 43.